


ESENTING CLINICAL SIGNS

DATE History: Murmur. Worsening cough. Started on pimobendan 5 mg SID, benazepril 5 mg SID a few weeks ago. Tachycardia.

10/25/21

ECHOCARDIOGRAPHIC FINDINGS

PERFORMED BY: 2D, M-mode, and Doppler study.

Dr. Meredith Swart There is severe left atrial dilation. The mitral valve leaflets are thickened, and a severe jet of mitral regurgitation is present. There is severe left ventricular dilation. Left ventricular systolic function is mildly hyperdynamic. The aorta and aortic valve are normal. Right atrial and right ventricular dimensions are normal. The tricuspid valve leaflets are mildly thickened, and a mild jet of tricuspid regurgitation is present. TR velocity does not suggest the presence of pulmonary hypertension. The pulmonary artery and pulmonic valve are normal. No pericardial effusion or cardiac masses are seen.

INTERPRETED BY

Keith Blass, DVM,
MS, DACVIM
(Cardiology)

An irregular heart rhythm is present.

PATIENT

Rowdy Calhoun

LA – 45.4 mm
LVIDd – 44.2 mm
LVIDs – 24.5 mm
FS – 44.6%

SPECIES

Canine

RA – 34.7 mm
RVFWd – 17.4 mm
LVOT – 1.66 m/s
RVOT – 0.69 m/s
TR – 2.50 m/s

BREED

Australian Shepherd

ASSESSMENT/RECOMMENDATIONS

Degenerative mitral and tricuspid valve disease
Arrhythmia – open

SEX

MN

AGE

11 y

This examination demonstrates regurgitation of blood across Rowdy's mitral and tricuspid valve disease. Rowdy's tricuspid valve disease is mild, as evidenced by his absence of secondary right heart chamber dilation. His mitral valve disease is significantly more advanced, as Rowdy has severe mitral regurgitation present, with severe secondary dilation of both his left atrium and left ventricle. Given the severity of his disease, it's very likely that mainstem bronchial compression is contributing to Rowdy's cough. In addition to coughing, Rowdy is at high risk for the development of exercise intolerance, syncope, and/or labored breathing, therefore, careful monitoring for these signs is recommended.

Rowdy's heart rhythm appears to be irregular, therefore, an ECG is recommended for further evaluation.

WEIGHT

22.6 lb

Rowdy's current medications are appropriate, though I recommend diving his pimobendan dose to 2.5 mg BID, while increasing his benazepril dose to 5 mg BID. I also recommend starting Rowdy on hydrocodone (2.5 mg PRN, up to every 6 hours). Should Rowdy's cough persist, a trial with furosemide (10 mg BID) may be warranted. Additional therapy may be warranted based on the results of the recommended ECG.

HOSPITAL NAME

Swart Veterinary
Imaging

A renal/electrolyte profile is recommended in 1-2 weeks. A recheck echocardiogram is recommended in 6-9 months. Thoracic radiographs are recommended if clinical signs compatible with congestive heart failure develop.

REFERRING VET

Dr. Swart



DATE

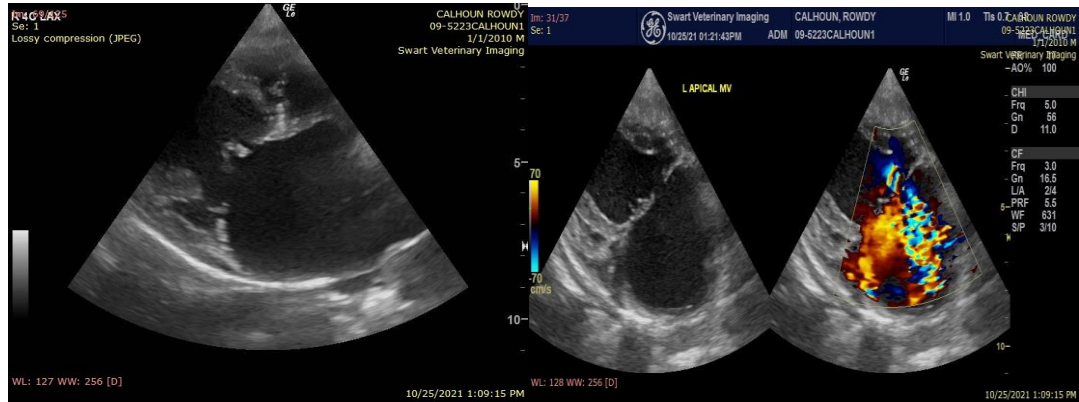
10/25/21

PERFORMED BY:

Dr. Meredith Swart

INTERPRETED BY

Keith Blass, DVM,
MS, DACVIM
(Cardiology)



PATIENT

Rowdy Calhoun

The information and recommendations provided are based on the images presented by the referring veterinarian. No evaluation can be communicated regarding pathology that was not visible in the image/video clips provided.

SPECIES

Canine

Thank you for this referral. If the clinical or image interpretation does not parallel your findings or if I can be of any further assistance please contact me.

BREED

Australian Shepherd

Keith Blass, DVM, MS, DACVIM (Cardiology)
KeithBlass@gmail.com
631-804-5754

SEX

MN

AGE

11 y

WEIGHT

22.6 lb

HOSPITAL NAME

Swart Veterinary
Imaging

REFERRING VET

Dr. Swart